Breast Cancer Res Treat (2017) 165:499–504
DOI 10.1007/s10549-017-4367-5

REVIEW

Predictive factors on outcomes in metaplastic breast cancer

C. Marc Leyrer[1] · Camille A. Berriochoa[1] · Shree Agrawal[1] · Alana Donaldson[1] · Benjamin C. Calhoun[1] · Chirag Shah[1] · Robyn Stewart[1] · Halle C. F. Moore[1] · Rahul D. Tendulkar[1]

Received: 13 June 2017 / Accepted: 27 June 2017 / Published online: 8 July 2017
© Springer Science+Business Media, LLC 2017

Abstract

Purpose Metaplastic breast cancer (MBC) is a rare, aggressive variant of breast cancer, with limited data available regarding treatment and outcomes. This study aims to review patients with MBC treated at our tertiary care institution with an emphasis on the role of treatment modality and histologic classification.

Methods With IRB-approval, we queried our pathology database for patients with MBC diagnosis. All cases were re-evaluated by dedicated breast pathologists and confirmed as MBC breast cancer. Patient demographics, clinical/pathologic histology, and treatment were analyzed with respect to outcomes including local–regional recurrence (LRR), distant metastasis (DM), and overall survival (OS). Univariate and multivariate Cox proportional hazards models were performed to evaluate the impact on outcomes. Kaplan–Meier methods estimated survival.

Results We evaluated 113 patients with MBC diagnosed between 2002 and 2013. Median age was 61 years and median pathologic tumor size 2.5 cm; 76 (67%) were ER/PR/Her2 negative, 83 (74%) grade 3. Median follow-up was 38 months. 47 (42%) underwent breast conservation therapy (BCT), 66 (58%) had mastectomy, 61 (54%) underwent adjuvant radiation (RT), and 85 (75%) had chemotherapy. At 2 and 5 years, the LRR/DM/OS rates were 12%/15%/90% and 21%/35%/69%, respectively. On Cox regression analysis, only adjuvant RT correlated with reduced LRR [RR 3.1 (1.13–9.88), $p = 0.027$], while chemotherapy, type of surgery, and T-N stage did not. Only T-stage ($p = 0.008$) correlated with DM, however chemotherapy, RT, surgery type, and N-stage were not. Univariate analysis demonstrated histologic subtype did not significantly correlate with local ($p = 0.54$) or distant ($p = 0.83$) disease control.

Conclusions This study represents among the largest institutional experiences in the outcomes of MBC. At this time, there does not appear to be a clear histologic subset of MBC which has significantly different clinical outcomes from the other subtypes. Although limited in its sample size, this study shows RT remains important in local–regional control.

Keywords Metaplastic · Local control · Triple-negative · Breast cancer · Radiation therapy · Chemotherapy · Retrospective · Review

Introduction

Breast cancer represents the most common cancer diagnosis among women in the United States with an estimated 249,260 new cases diagnosed in 2016 [1]. Less than 1% of these individuals are diagnosed with metaplastic breast cancer (MBC) based on histopathologic findings [2–5]. MBC can be further classified based on the epithelial or mesenchymal components into several subtypes of MBC, including spindle, squamous, mixed, and matrix-producing MBC [6–9]. Previous studies have demonstrated MBC to be a relatively aggressive tumor with poor outcomes, particularly when compared to invasive ductal carcinoma, no special type [10–14]. Most MBCs represent a subset of triple-negative breast cancer (TNBC); however, not all MBCs fulfill these criteria [15].

While there is no standard of care for the treatment of MBC outside of normal breast cancer treatment paradigms, the suggestion of worse outcomes compared with more common

✉ C. Marc Leyrer
leyrerc@ccf.org

[1] Cleveland Clinic Foundation, Cleveland, OH, USA

histologies may lead to more aggressive treatment (through increased use of mastectomy/chemotherapy) as shown in a previous National Cancer Database (NCDB) analysis [5]. There is some suggestion that spindle cell MBC and MBC with heterologous matrix-producing components may be associated with a particularly worse prognosis [9, 16, 17]. However there are conflicting data regarding histologic subtype and correlation with clinical outcomes [18, 19]. Given the limited literature and rarity of this disease, we reviewed the clinical and pathologic characteristics of patients with MBC treated at our high volume, tertiary care institution, along with the treatment outcomes with an emphasis on the role of treatment modality and histologic classification.

Methods

With IRB-approval, we queried our pathology database for patients with a MBC diagnosed between 2002 and 2013 at our institution. Those who were male, had metastatic disease at diagnosis, did not receive treatment at our institution, or did not have pathology slides available were excluded from this analysis. Each case of MBC was reviewed by a dedicated breast pathologist at our institution to confirm the histologic diagnosis. MBC was further categorized as squamous, spindle cell, matrix producing, or other. Hormone receptor and HER2 status were obtained from the original pathology reports. An immunohistochemical stain of >1% was used to determine ER and PR positivity after the publication of the American Society of Clinical Oncology/College of American Pathologists (ASCO/CAP) guidelines [20]. Prior to the publication of the guidelines the cutoff for hormone receptor positivity was 5%. HER2 status was determined primarily by fluorescence in situ hybridization (FISH) and interpreted under the 2007 ASCO/CAP Guidelines [21].

One-hundred and twenty-three cases were identified and reviewed for their demographics, clinical/pathologic tumor histology, and treatment modalities with respect to outcomes including local–regional recurrence (LRR), distant metastasis (DM), and overall survival (OS). Of these patients, ten were ultimately not included in our analysis: one was determined on repeat pathology review not to have MBC, six had metastatic disease at diagnosis, and three had no follow-up and/or refused treatment. Univariate and multivariate Cox proportional hazards models were performed to evaluate the impact on outcomes on radiation therapy (RT), chemotherapy, histologic subtype, clinical T/N stage, and tumor grade. Kaplan–Meier methods estimated survival with survival rates presented with their 95% confidence intervals. Data were analyzed using IBM SPSS Statistics software version 24.

Results

One-hundred thirteen patients received treatment for a confirmed diagnosis of MBC. Clinical and pathologic characteristics are outlined in Table 1 below with a median follow-up period of 35 months (range 3–133 months). Median age was 61 years old (range 27–95 years) with the majority of patients being post-menopausal (75%). Most

Table 1 Clinical and pathologic demographics

Patient demographics			
Total patients			113
Median age at diagnosis (mos)			61 (27–95)
Median F/u period (mos)			38 (3–133)
Pre-menopausal			28 (25%)
Post-menopausal			85 (75%)
Location			
Left sided			58 (51%)
Right sided			55 (49%)
Race			
Caucasian			74 (66%)
African American			25 (22%)
Asian			4 (4%)
Tumor characteristics			
Grade			
1			5 (5%)
2			10 (9%)
3			83 (74%)
LVSI+			33 (29%)
ECE+			8 (7%)
LN+			24 (21%)
Hormone characteristics			
ER+			22 (20%)
PR+			11 (10%)
HER2+			13 (12%)
Triple Negative			76 (67%)
Clinical stage			
T1	30 (27%)	N0	94 (83%)
T2	67 (60%)	N1	15 (13%)
T3	9 (8%)	N2	2 (2%)
T4	4 (4%)	Nx	2 (2%)
Tx	3 (3%)		
Pathologic stage[a]			
T0	9 (8%)	N0	81 (72%)
T1	30 (27%)	N1	14 (12%)
T2	59 (52%)	N2	7 (6%)
T3	11 (10%)	N3	2 (2%)
T4	4 (4%)	Nx	9 (8%)

[a] Includes patients receiving both adjuvant and neoadjuvant therapy

patients were clinically diagnosed with T2 disease (59%) and were cN0 (83%), with pathologic staging remaining similar after surgical resection (52 and 93%, respectively). Median clinical tumor size was 3.0 cm (range 0.8–14 cm), and median pathologic tumor size was 2.5 cm (range 0–13 cm). Of the six patients who were excluded due to metasstatic disease, five had metastatic disease to the lung, two to bone, and one to brain at initial diagnosis.

Overall, only 46 (41%) were identified as MBC at the initial biopsy; the remainder were diagnosed at the time of surgical resection. Ninety-seven (94%) patients had a high combined histologic grade (Nottingham) [22]. Of the histologic subtypes, 13 (12%) had spindle cell features, 51 (45%) were squamous, 22 (19%) were matrix producing, 27 (24%) had other histology (e.g., sarcoma, not otherwise specified). Thirty-three (29%) patients were found to have lymphovascular space invasion (LVSI). Overall, 24 (21%) had lymph node positive disease on resection with eight having extracapsular extension (ECE). The majority of these LN-positive patients (18) had squamous histology on subtype classification with a low number of positive nodes (median = 2 positive lymph nodes). Overall, 76 (67%) patients had triple-negative MBC; 23 (20%) were hormone receptor positive, 13 (12%) were HER2-amplified (of whom 11 received trastuzumab-based systemic therapy), and 1 had unknown receptor status.

Forty-seven patients underwent breast-conserving surgery (BCS) and 66 had a mastectomy. Sixty-one patients received adjuvant radiation therapy. Median total dose was 6000 cGy (range 4256–6640 cGy), 40 patients received a tumor bed boost, and 11 (23%) did not receive radiation after BCS. Of the 47 patients with known treatment plans, 19 (40%) received regional nodal radiation. Among the 36 BCT patients who received RT, there was 1 (17%) case of local recurrence and 1 (6%) case of axillary recurrence. Ten patients who underwent BCS developed metastatic disease to one or more location. Sixteen patients who underwent mastectomy failed distantly to one or more location. Among the patients undergoing mastectomy, there were 5 (25%) cases of chest wall recurrence, 2 (8%) cases of axillary recurrence, and one (4%) case of supraclavicular recurrence. Two (40%) of the patients with chest wall, and 1 (100%) with supraclavicular, recurrence received RT. Of the 26 patients with metastatic disease, 10 (38%) were found to have concomitant local–regional recurrence (LRR).

Eighty-five (75%) of patients received systemic chemotherapy. Sixty-six patients received adjuvant chemotherapy after initial surgery with a variety of chemotherapy regimens. Twenty-three patients (20%) received neoadjuvant chemotherapy. Pathologic complete response (pCR) was observed in 9 of 23 patients (39%). No patients had a positive margin after neoadjuvant chemotherapy with four (17%) having a close margin ($\leq$2 mm). Only one patient with a pCR had a DM (1/9, 11%), and none had LRR. Fourteen of the 23 neoadjuvantly treated patients did not have a pCR; among them, 7 (50%) ultimately had DM and 2 (14%) had LRR.

With a median follow-up period of 37.8 months (range 2.6–133.7 months), the 2 year local–regional recurrence, distant metastatic, and overall survival rates were 12, 15, and 90%, respectively. At 5 years, the LRR, DM, OS rates were 21, 35, and 69%, respectively (Fig. 1). On multivariate analysis, only adjuvant radiation was correlated with LRR, while chemotherapy use, surgery type (BCT/mastectomy), and T/N stage were not (Fig. 2). Not

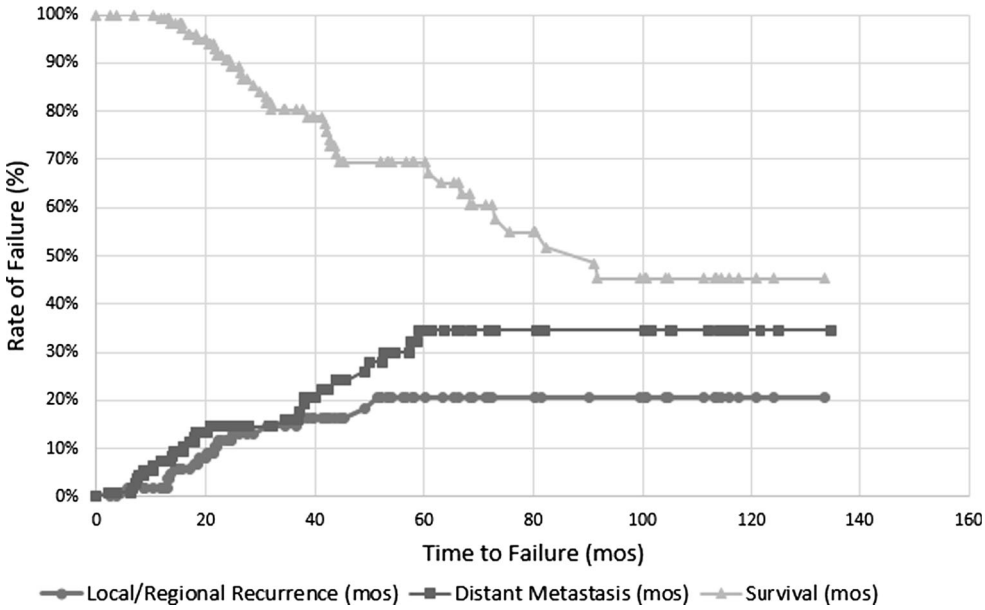

Fig. 1 Rate of failure for metaplastic breast cancer

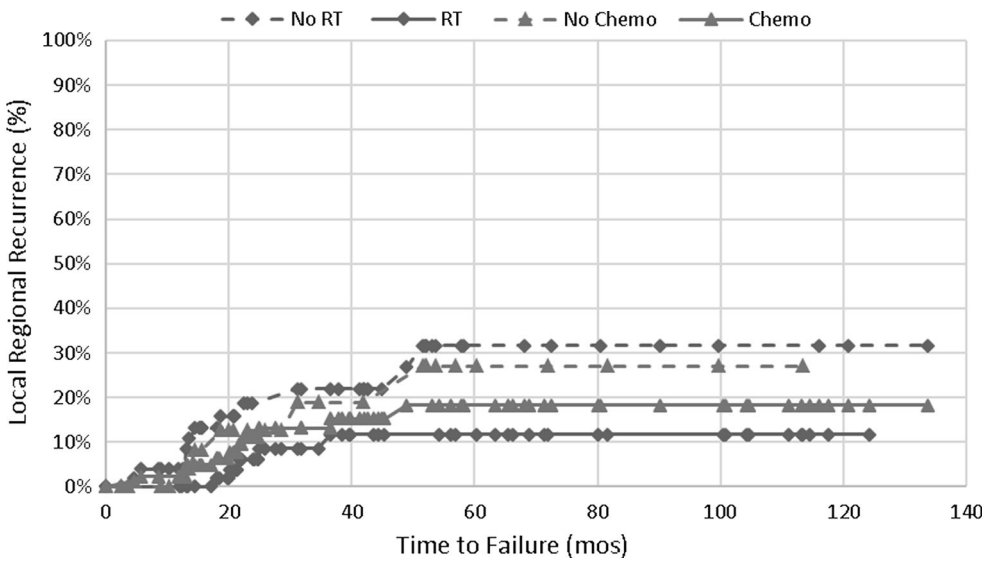

Fig. 2 Local–regional recurrence by treatment

having radiation after resection was associated with a RR of 3.1 [(1.13–9.88), $p = 0.027$] for LRR. In terms of DM, multivariate analysis showed T-stage to be significantly correlated with metastatic disease ($p = 0.008$); however, chemotherapy, radiation therapy, surgery type, and N-stage were not.

Chemotherapy was not significant for OS, DM, or LRR when based on the type of surgical resection a patient received. However, when radiation therapy was stratified by surgery type, receipt of adjuvant radiation after BCS was significant for improved LRR ($p < 0.001$) and OS ($p = 0.009$) over those who did not. The use of radiation therapy was not significantly associated with LRR, DM, or OS for mastectomy.

Univariate analysis demonstrated that histologic subtype did not significantly correlate with local ($p = 0.54$) or distant ($p = 0.83$) disease control. Two year local control rates per Kaplan–Meier analysis are as follows: spindle 77%, squamous 90%, matrix- producing 97%, and other 97%, with no statistically significant difference among subtypes ($p = 0.54$). For the same histologic subtypes, 2-year distant metastasis-free survival distant control rates were 84, 87, 86, and 81%, respectively ($p = 0.83$).

Discussion

MBC is recognized as a discrete pathologic subset of breast cancer with unique prognostic factors and outcomes. The majority of published studies on MBC have been relatively small with conflicting results. To the best of our knowledge, this is the largest single institutional study of histologically confirmed MBC cases in the literature to date. Our study showed that the majority of MBC's tend to have a high histologic grade and propensity for hormone receptor negativity with lower HER-2 expression, a finding that is consistent with previously published literature [15, 23, 24] While prior studies have shown poorer outcomes when compared to TNBC, MBC patients as a whole have worse outcomes than their counterparts with IDC with 5-year survival rates of 49–69%, which is comparable with our outcomes [13, 16, 25, 26].

Importantly, our study showed that those who did not have RT had a higher risk of LRR (RR 3.1, p −0.027) regardless of the other treatments they received. Consistent with previous evaluations of BCT, adjuvant RT is associated with both improved LRR ($p = 0.009$) and OS ($p < 0.001$). Although this did not remain significant in mastectomy patients who received treatment at the physician discretion, it underscores the role of RT in the treatment of patients with MBC. There may be a role for consideration of post-mastectomy RT in certain high-risk patients; however, it is not possible to make substantive conclusions given our limited sample size.

MBC tends to present with larger tumors leading to a higher T-stage at diagnosis when compared to IDC. The results of the NCDB analysis were similar in distribution of T-staging to our outcomes for MBC [5]. While patients tended to have a low number of positive nodes, the overall survival at 5 years was still poor. This could be due to the risk of hematogenous spread in MBC (versus lymphatic) and may explain for the higher rate of distant metastatic disease as compared to the more regional lymphatic spread observed in IDC [3, 18].

Of increasing interest is the role of histologic subtype on outcomes. The squamous cell subtype can be identified by the infiltrating squamous cells with eosinophilic cytoplasm and polygonal cells [27]. The spindle subtype is associated with poorly cohesive sheets of atypical spindle cells, and this is thought to be more aggressive than the matrix type

identified by its cartilaginous or osseous stromal matrix without spindle cells [8, 9, 16, 17, 28]. While these can be difficult to differentiate on histopathology, we found no association between subtypes and outcomes including LR, DM, and OS. The majority of LN-positive patients were of squamous histology which has been previously described as presenting with a less advanced T-stage when compared to mixed spindle/squamous, and spindle cell histology [17]. While the squamous subtype may present with a lower T-stage (only four were T3/4), they may have a higher propensity for LN+ disease and a higher propensity for distant spread. Among these patients only four of the LN+ squamous cell patients had local recurrence, while nine eventually presented with metastatic disease.

While histologic subtype did not play a role on our outcomes, there may be a role for further genetic analysis in these patients. The intrinsic molecular subtypes of the majority of TNBC are either basal-like or claudin-low with a minority of HER2-enriched tumors [29]. The claudin-low intrinsic subtype is known to include metaplastic carcinomas and to have a poor prognosis [29]. It is worth noting that claudin-low and metaplastic tumors are both enriched for molecular and phenotypic markers of epithelial-to-mesenchymal transition (EMT) and cancer stem cells [29, 30]. Future studies could include gene expression analysis of the tumors in this series to determine the distribution of intrinsic molecular subtypes and confirm the poor prognosis of the claudin-low subtype.

It is important to note that MBC can also be difficult to identify on biopsy, with only 41% of our cases identified preoperatively on initial image-guided core biopsy. MBC typically presents in older women, is associated with a palpable breast mass, and is often ill-defined on imaging [4]. However, once diagnosed, these patients tend to be treated with more aggressive treatment regimens including mastectomy and/or chemotherapy. MBC typically has been shown to have a poorer response to chemotherapy when compared to IDC [3, 13]. Those who do have a pCR still have better outcomes; as described above, the DM rate observed in this series for those who had pCR was 11% versus the 50% rate observed in those without pCR.

The majority (75%) of our patients received chemotherapy; however, there was no significant improvement in OS, DM, or LRR seen within our cohort of patients. While it is difficult to draw conclusions from our evaluation given the diverse nature of both type and timing of chemotherapy, this is consistent with previous studies showing a more limited response to systemic therapy in MBC [13, 31, 32]. This has led to investigations of more novel strategies and targeted therapies in the treatment of MBC which have shown some promise [33–35]. However, this will require continued investigation in further reviews and clinical trials to further determine efficacy.

The present study does have limitations. The patient size is small, along with a smaller number of events, for ascertaining conclusions regarding survival outcomes which may be appreciable with a larger population. Also, some patients may have received RT or chemotherapy elsewhere without documentation in their institutional follow-up visits. We may also require more patients before we are able to show an appreciable difference in outcomes histologic subtype of MBC.

Conclusion

The overall prognosis observed in MBC is poor, with high rates of DM (35% at 5 years); fortunately, the prevalence of this aggressive subtype is limited but as a result, the optimal treatment strategy remains elusive [10–14]. At this time there does not appear to be a clear histologic subset of MBC which has significantly different clinical outcomes from the other subtypes. Although limited in its sample size, this study shows RT remains important in local–regional control.

Compliance with ethical standards

Conflict of interest Dr. Chirag Shah is a scientific consultant with Impedimed Inc.

References

1. Siegel RL, Miller KD, Jemal A (2016) Cancer statistics, 2016. CA Cancer J Clin 66(1):7–30
2. Fritz AG (2000) International classification of diseases for oncology: ICD-O, 3rd edn. World Health Organization, Geneva, p 240
3. Tzanninis IG et al (2016) Management and outcomes in metaplastic breast cancer. Clin Breast Cancer 16(6):437–443
4. Leddy R et al (2012) Review of metaplastic carcinoma of the breast: imaging findings and pathologic features. J Clin Imaging Sci 2:21
5. Pezzi CM et al (2007) Characteristics and treatment of metaplastic breast cancer: analysis of 892 cases from the National Cancer Data Base. Ann Surg Oncol 14(1):166–173
6. Pp R (2009) Rosen's breast pathology. Lippincott Williams & Wilkins, Philadelphia
7. Lakhani S, Ellis I, Schnitt S et al (2012) WHO classification of tumours of the breast, 4th edn. IARC, Lyon, pp 48–52
8. Wargotz ES, Deos PH, Norris HJ (1989) Metaplastic carcinomas of the breast. II. Spindle cell carcinoma. Hum Pathol 20(8):732–740
9. Downs-Kelly E et al (2009) Matrix-producing carcinoma of the breast: an aggressive subtype of metaplastic carcinoma. Am J Surg Pathol 33(4):534–541
10. Jung SY et al (2010) Worse prognosis of metaplastic breast cancer patients than other patients with triple-negative breast cancer. Breast Cancer Res Treat 120(3):627–637
11. Lai HW et al (2013) The prognostic significance of metaplastic carcinoma of the breast (MCB)—a case controlled comparison study with infiltrating ductal carcinoma. Breast 22(5):968–973
12. Nelson RA et al (2015) Survival outcomes of metaplastic breast cancer patients: results from a US population-based analysis. Ann Surg Oncol 22(1):24–31

13. Rayson D et al (1999) Metaplastic breast cancer: prognosis and response to systemic therapy. Ann Oncol 10(4):413–419
14. Song Y et al (2013) Unique clinicopathological features of metaplastic breast carcinoma compared with invasive ductal carcinoma and poor prognostic indicators. World J Surg Oncol 11:129
15. Rakha EA et al (2017) Immunoprofile of metaplastic carcinomas of the breast. Histopathology 70(6):975–985
16. Cimino-Mathews A et al (2016) A clinicopathologic analysis of 45 patients with metaplastic breast carcinoma. Am J Clin Pathol 145(3):365–372
17. Rakha EA et al (2015) Prognostic factors in metaplastic carcinoma of the breast: a multi-institutional study. Br J Cancer 112(2):283–289
18. McKinnon E, Xiao P (2015) Metaplastic carcinoma of the breast. Arch Pathol Lab Med 139(6):819–822
19. Zhang Y et al (2015) Clinicopathological features and prognosis of metaplastic breast carcinoma: experience of a major chinese cancer center. PLoS ONE 10(6):e0131409
20. Hammond ME et al (2010) American Society of Clinical Oncology/College of American Pathologists guideline recommendations for immunohistochemical testing of estrogen and progesterone receptors in breast cancer (unabridged version). Arch Pathol Lab Med 134(7):e48–e72
21. Wolff AC et al (2013) Recommendations for human epidermal growth factor receptor 2 testing in breast cancer: American Society of Clinical Oncology/College of American Pathologists clinical practice guideline update. J Clin Oncol 31(31):3997–4013
22. Elston CW, Ellis IO (2002) Pathological prognostic factors in breast cancer. I. The value of histological grade in breast cancer: experience from a large study with long-term follow-up. Histopathology 41(3A):154–161
23. Bae SY et al (2011) The prognoses of metaplastic breast cancer patients compared to those of triple-negative breast cancer patients. Breast Cancer Res Treat 126(2):471–478
24. Beatty JD et al (2006) Metaplastic breast cancer: clinical significance. Am J Surg 191(5):657–664
25. Luini A et al (2007) Metaplastic carcinoma of the breast, an unusual disease with worse prognosis: the experience of the European Institute of Oncology and review of the literature. Breast Cancer Res Treat 101(3):349–353
26. Oberman HA (1987) Metaplastic carcinoma of the breast. A clinicopathologic study of 29 patients. Am J Surg Pathol 11(12):918–929
27. Wargotz ES, Norris HJ (1990) Metaplastic carcinomas of the breast. IV. Squamous cell carcinoma of ductal origin. Cancer 65(2):272–276
28. Chuthapisith S et al (2013) Metaplastic carcinoma of the breast with transformation from adenosquamous carcinoma to osteosarcomatoid and spindle cell morphology. Oncol Lett 6(3):728–732
29. Prat A et al (2010) Phenotypic and molecular characterization of the claudin-low intrinsic subtype of breast cancer. Breast Cancer Res 12(5):R68
30. Zhang Y, Toy KA, Kleer CG (2012) Metaplastic breast carcinomas are enriched in markers of tumor-initiating cells and epithelial to mesenchymal transition. Mod Pathol 25(2):178–184
31. Esbah O et al (2012) Metaplastic breast carcinoma: case series and review of the literature. Asian Pac J Cancer Prev 13(9):4645–4649
32. Chen IC et al (2011) Lack of efficacy to systemic chemotherapy for treatment of metaplastic carcinoma of the breast in the modern era. Breast Cancer Res Treat 130(1):345–351
33. Brown-Glaberman U, Graham A, Stopeck A (2010) A case of metaplastic carcinoma of the breast responsive to chemotherapy with Ifosfamide and Etoposide: improved antitumor response by targeting sarcomatous features. Breast J 16(6):663–665
34. Shah DR, Tseng WH, Martinez SR (2012) Treatment options for metaplastic breast cancer. ISRN Oncol 2012:706162
35. Abouharb S, Moulder S (2015) Metaplastic breast cancer: clinical overview and molecular aberrations for potential targeted therapy. Curr Oncol Rep 17(3):431